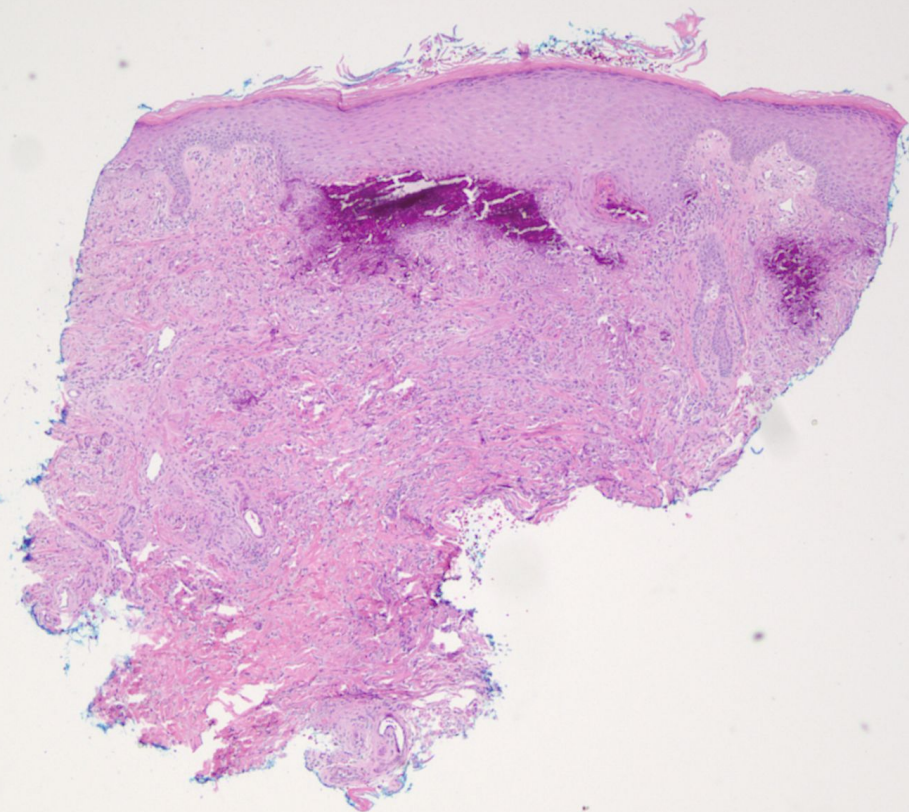
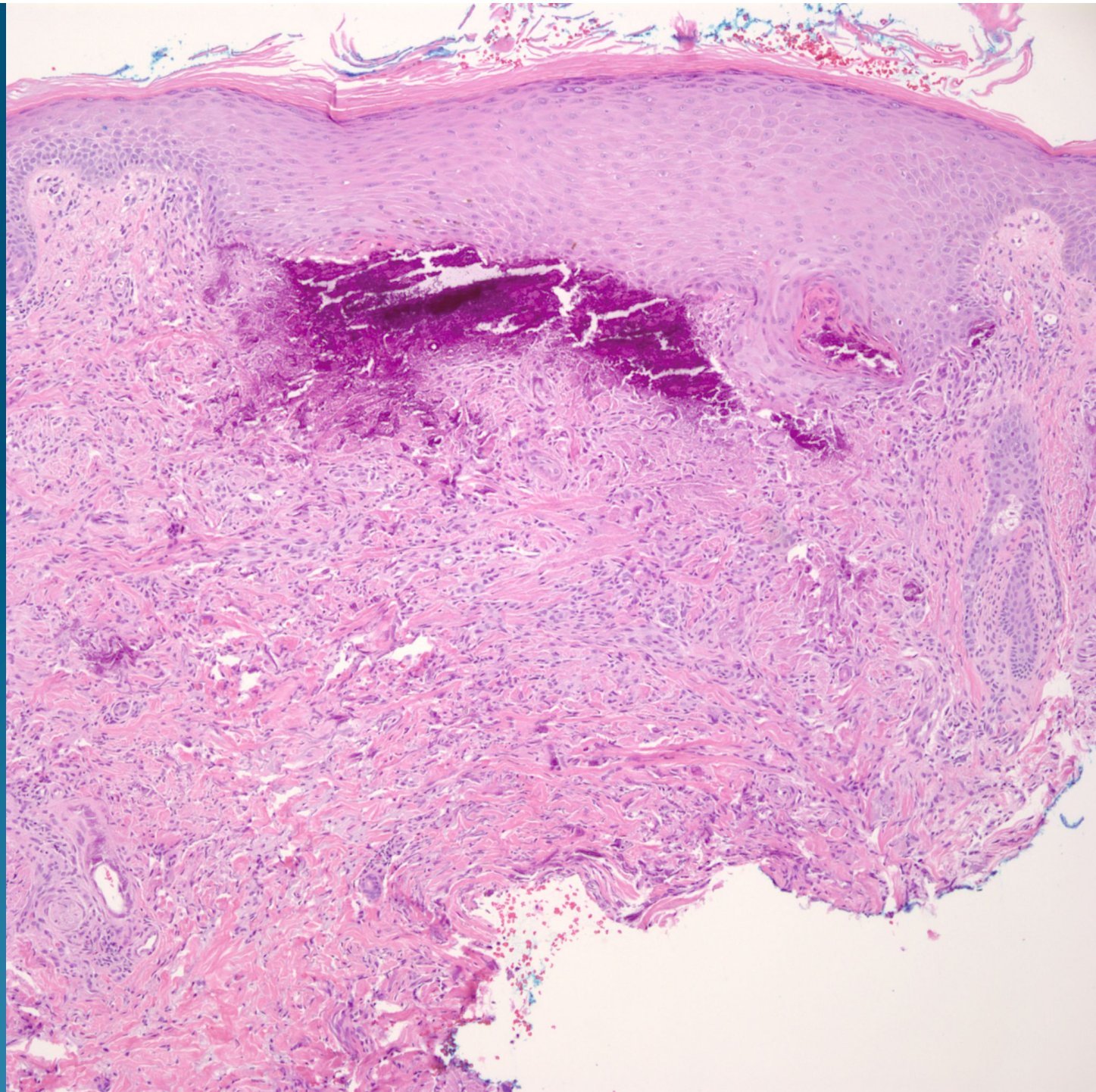
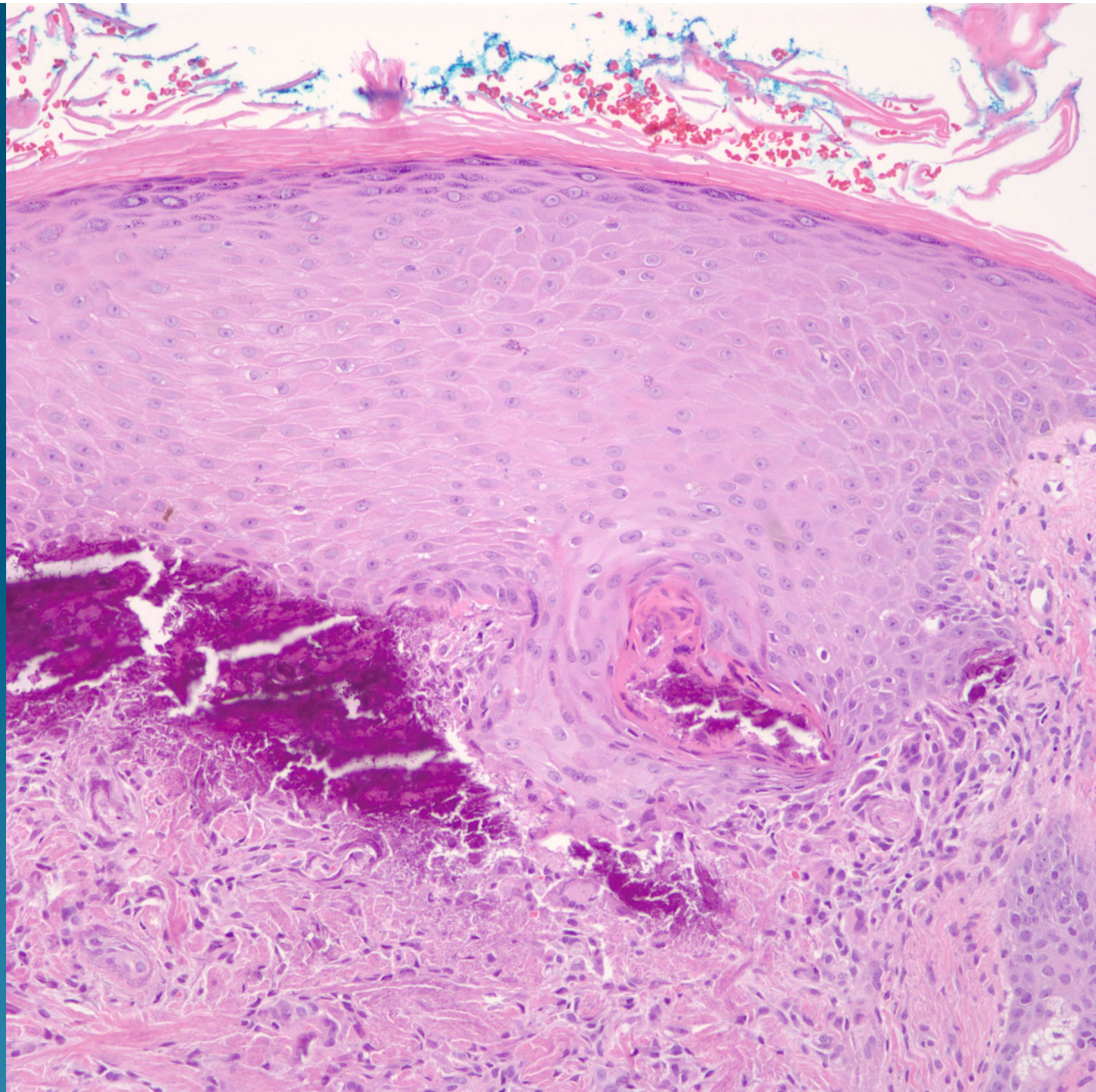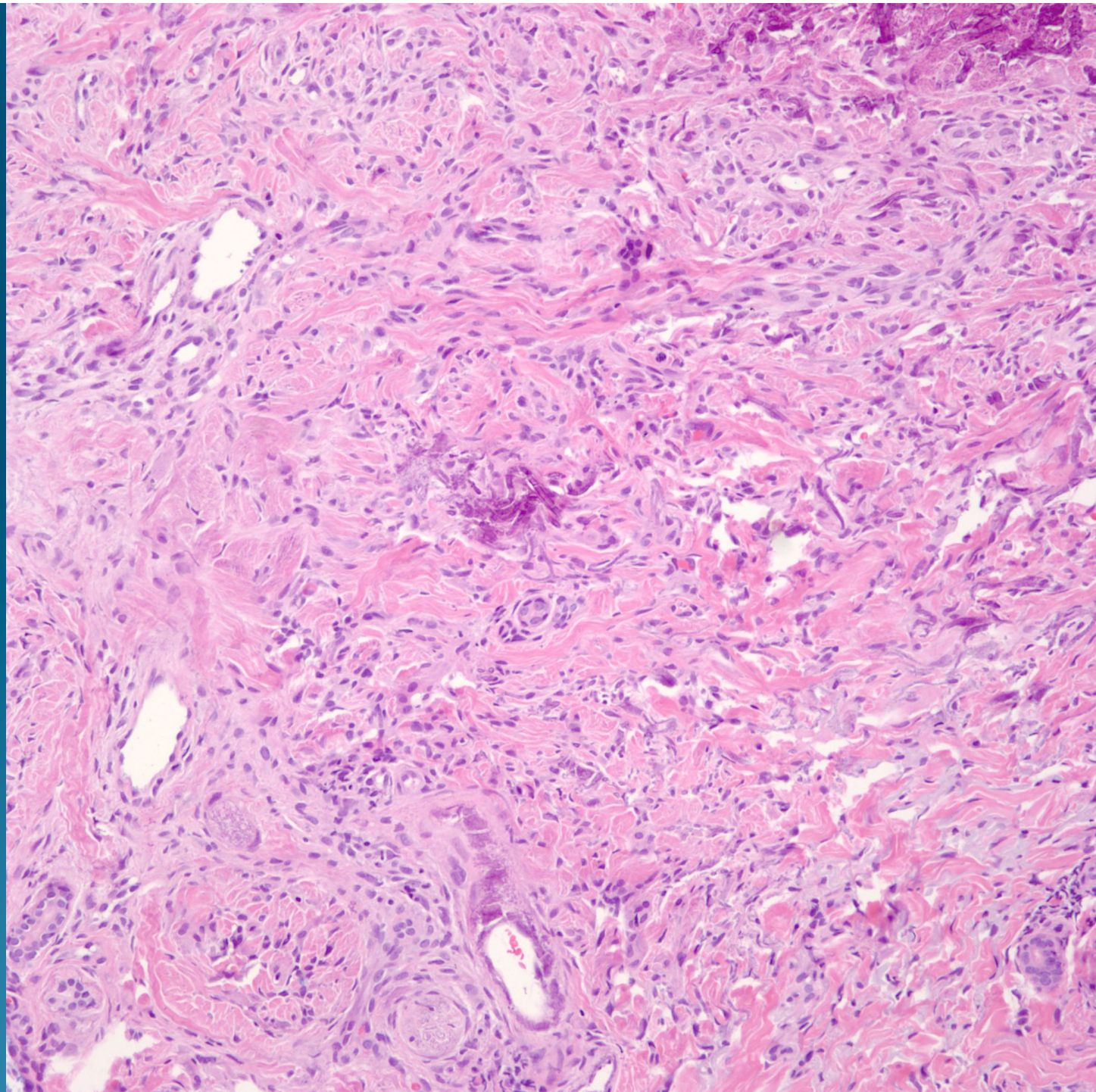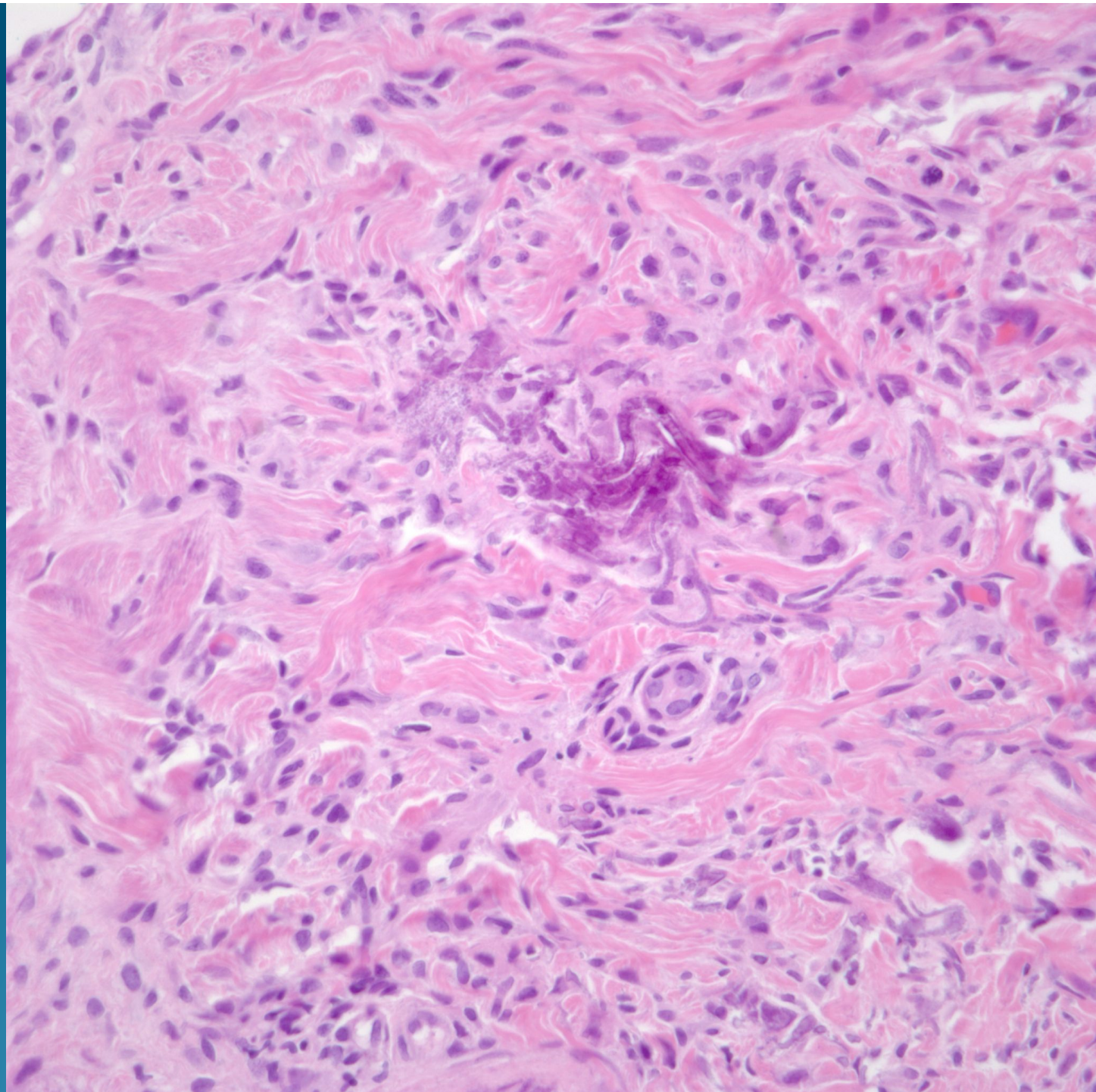# What is the best diagnosis?

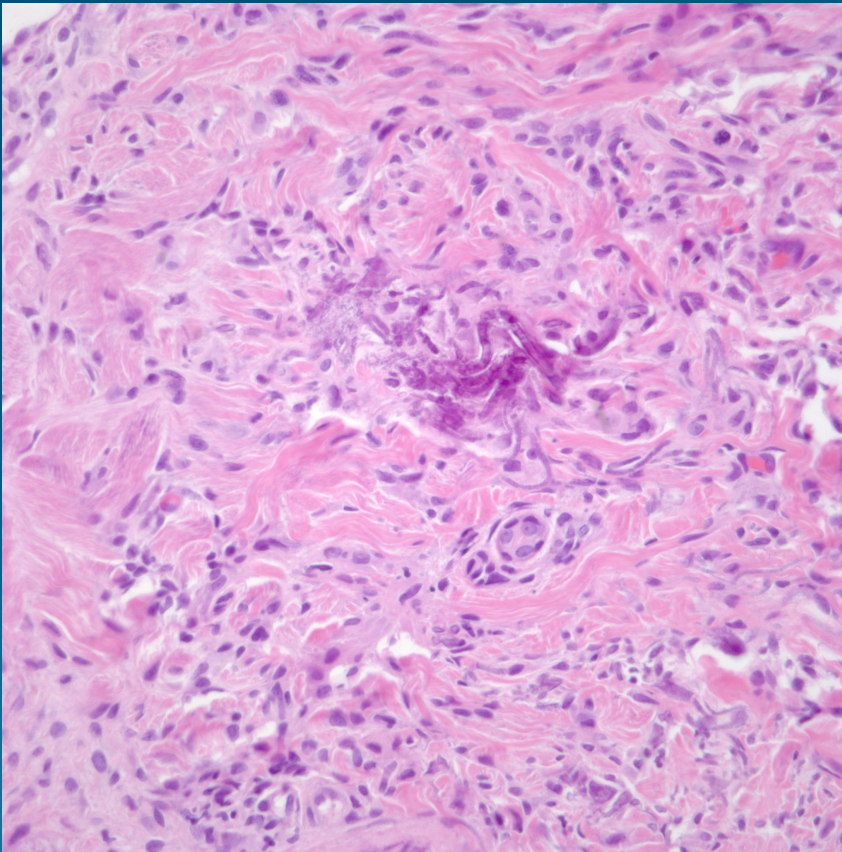
- A. Elastosis perforans serpiginosa
- B. Pseudoxanthoma elasticum
- C. Nephrogenic systemic fibrosis
- D. Necrobiosis lipoidica
- E. Calciophylaxis

# Pseudoxanthoma elasticum





# Pearls



- Serpiginous elastic fibers encrusted with calcium
- May rarely occur with perforation
- Primary versus secondary causes, correlation with clinical presentation